



Effect of Implant-Abutment Connection Type on Bone Around Dental Implants in Long-Term Observation: Internal Cone Versus Internal Hex

Adam Szyszkowski, MD, DMD* and Marcin Kozakiewicz, DMD†

The construction of the implant-abutment connection is one of the main factors that allowed for the development of implant dentistry to its present state. The external hexagonal connection mainly used in the past proved to be mechanically and biologically unfavorable. This external hexagon connection showed a greater tendency to fracture compared with other connection types.¹ It also caused greater microgaps between implant and abutment, and provoked microleakage and bacterial colonization.^{2–5} As a result of the poor external hex outcome, the connection was transferred beneath the implant platform, creating an internal hex. This placement ensured a more stable implant-abutment connection and the dissipation of loading force along the implant walls.² Over time, modifications to this connection developed, one of which was the internal Morse taper.

The purpose of this study was to evaluate the effect of the implant-abutment connection on bone loss

Purpose: The purpose of this study was to evaluate the influence of the implant-abutment connection type on the bone level around dental implants in long-term observation and the survival rate for the different types of implant-abutment connections.

Materials and Methods: Two groups of implants made of titanium grade 23 alloy and with sandblasted and acid-etched (SLA) surface were included in the study: (a) the internal hex implant-abutment connection group (480 SPI dental implants; Alpha-Bio Tec, Petach Tikva, Israel, 184 patients) and (b) the internal cone implant-abutment connection group (60 CI dental implants; MIS Implant Technologies, Shlomi, Israel, 34 patients). Certain inclusion and exclusion criteria were applied. Marginal bone loss (MBL) around the dental implants was measured in intraoral radiographs taken with parallel technique with a film holder and by bite recording index.

X-rays were performed at the moment of functional loading, and at 12, 24, 36, and 60 months after loading. The digital analysis was conducted using Dental Studio 2.0 computer software.

Results: Average MBL was significantly lower in the conical connection compared with internal hex group— 0.68 ± 0.59 versus 0.99 ± 0.89 mm (12 months), 0.78 ± 0.80 versus 1.12 ± 1.00 mm (24 months), 0.83 ± 0.87 versus 1.22 ± 1.03 mm (36 months), and 0.96 ± 1.02 versus 1.30 ± 1.15 mm (60 months after loading). Both groups of implants achieved a 100% survival rate.

Conclusion: The internal cone connection reduced bone resorption compared with the internal hex. Both groups of implants had a 100% survival rate. (Implant Dent 2019;00:1–7)

Key Words: marginal bone loss, dental implants, dental digital radiography

*Assistant Professor, Department of Maxillofacial Surgery, Medical University of Lodz, Lodz, Poland.
†Professor, Department of Maxillofacial Surgery, Medical University of Lodz, Lodz, Poland.

Reprint requests and correspondence to: Adam Szyszkowski, MD, DMD, Department of Maxillofacial Surgery, Medical University of Lodz, ul. Cynarskiego 4/27, Lodz 92-447, Poland, Phone: +48606910669, Fax: +48426776793, E-mail: a_szyszkowski@len.pl

ISSN 1056-6163/19/00000-001
Implant Dentistry
Volume 00 • Number 00
Copyright © 2019 Wolters Kluwer Health, Inc. All rights reserved.

DOI: 10.1097/ID.0000000000000905

around dental implants and the survival rate in long-term follow-up.

MATERIALS AND METHODS

Two groups of implants were included in the retrospective study:

1. Four hundred eighty SPI dental implants (Alpha-Bio Tec, Petach

Tikva, Israel) placed in 184 patients (43.8 ± 14.13 year olds, 100 females and 84 males). This group represented the internal hex implant-abutment connection.

2. Sixty MIS C1 dental implants (MIS Implant Technologies, Shlomi, Israel) placed in 34 patients (46.17 ± 13.73 year olds, 20




Fig. 1. Analysis of bone level on the distal implant surface at the time of functional loading and at 12, 24, 36, and 60 months after loading. Red line—primary bone level in the moment of functional loading [00M]; green arrow—MBL after 12 months [12 M]; yellow arrow—MBL after 24 months [24 M]; blue arrow—MBL after 36 months [36 M]; black arrow—MBL after 60 months [60 M].

females and 14 males). This group represented the internal cone implant-abutment connection.

Both types of implant systems were made of the same titanium alloy-grade 23 (Ti-6Al-4V-ELI) and had the same SLA (sandblasted and acid-etched) surface.⁶⁻⁸

Certain inclusion criteria were adopted:

1. One or more teeth extracted at least 4 months before implant placement
2. Sufficient bone volume to place implant without augmentation procedures
3. Absence of intraoral acute or chronic inflammation
4. Good oral hygiene
5. Absence of any systemic disease
6. Tests results within reference ranges (complete blood test, urinary calcium excretion, thyroid-stimulating hormone, parathyroid hormone and calcium serum level, and densitometry)

Exclusion criteria were:

1. Any systemic (ie, osteoporosis, diabetes) or mental illness
2. A history of drug or alcohol abuse

Informed consent was obtained from each patient about the use of materials for the experiment.

Surgical and Restorative Procedure

All the implantations were performed by the same experienced maxillofacial surgeon. A 2-g dose of amoxicillin was administered intraorally to the patient 60 minutes before the

surgery began. Under local anesthesia (Ubistesin Forte; 3M ESPE AG, Seefeld, Germany), mucous membrane was incised with a 15c scalpel blade on the top of the alveolar process. The bone was exposed after raising the mucoperiosteal flap, and then the osteotomy was performed with specific drills sequenced according to the manufacturers' guidelines. Dental implants were inserted with a hand torque-measuring ratchet to the level of the bone, and the insertion torque was recorded. Subsequently, a cover screw was placed and the wound was closed with nonresorbable sutures (Dafilon 4-0; B. Braun Medical Inc., Bethlehem, PA). Patients complied with the pharmacological regimen: 1 g oral amoxicillin every 12 hours for 6 days and 400 mg ibuprofen every 6 hours, as needed. In addition, 0.2% chlorhexidine rinses were prescribed (2/d for 14 days), and sutures were removed 2 weeks after surgery.

Healing periods ranged from 0 to 17 months, where 0 meant immediate loading with a temporary bridge. All other cases underwent closed healing, and then healing screws were inserted on the implants. For 2 weeks, the gingiva formed around the healing screws and dental impressions taken with Impregum Penta (3M ESPE AG) were sent to the dental technician. Approximately 2 weeks were required to perform and fix the final prosthetic appliances. Two types of prostheses were included in this study (crowns and bridges), all of which were screw-retained with torque values suggested by the manufacturers.⁹

Radiographic Examination

Radiological examinations were performed in a standardized manner at the following moments: immediately after loading, 12 months after loading, 24 months after loading, 36 months after loading, and 60 months after loading. Focus x-ray apparatus (Instrumental Dental, Tuusula, Finland) was set to the constant technical parameters: exposure time 0.1 seconds, voltage in the lamp 70 kV, and current 7 mA. An intraoral parallel technique was used. To ensure an identical relative position of the implant, x-ray tube, and radiation detector, a set of RINN XCP rings and holders was used (Dentsply International Inc., Cheung Sha Wan, Hong Kong) with a silicone bite index. The video part of the system was a recording plate coated with photosensitive storage phosphor (Digora Optime digital radiography system; Soredex, Tuusula, Finland). After the x-ray exposure, the plate was placed in a scanner that read radiographic information (the image size was 476×620 pixels; the pixel size was $70 \times 70 \mu\text{m}$). A computer coupled with the scanner processed, presented, and archived acquired images.

Radiographs Analysis

X-ray images were analyzed using Dental Studio 2.0 computer software by one person, on the same monitor. This analysis was performed each time in the following way:

1. The x-ray axis taken at loading [00 M] was corrected so that the dental implant took a vertical position.
2. Next x-rays from periods 12, 24, 36, and 60 months after loading (12, 24, 36, 60 M, respectively) were geometrically aligned in such a way that the dental implant on each of the images ideally overlapped the implant from the x-ray taken at the time of loading, rotated to the vertical position [00 M]. The implants were treated as geometric indicators—reference areas.
3. On the geometrically aligned radiographs, the most coronal bone to implant contact in the mesial

Table 1. Number of Implants and Patients and Frequency of Implants and Patients in Relation to the Analyzed Factors in the Two Implant Groups

Factor	Level	Group 1—480 Internal Hex SPI Implants				Group 2—60 Internal Cone C1 Implants			
		No. of Patients	% of Patients	No. of Implants	% of Implants	No. of Patients	% of Patients	No. of Implants	% of Implants
Sex	Male	84	45.65	242	50.42	14	41.18	18	30.00
	Female	100	54.35	238	49.58	20	58.82	42	70.00
Implantation site	Maxilla	106	57.61	268	55.83	22	64.70	26	43.33
	Mandible	78	42.39	212	44.17	12	35.30	34	56.67
Implantation site	Frontal	70	38.04	174	36.25	14	41.18	14	23.33
	Lateral	114	61.96	306	63.75	20	58.82	46	76.67

Group 1 indicates 480 internal hex SPI implants; group 2, 60 internal cone C1 implants.

and distal aspects of the implant neck was marked separately (Fig. 1).

- The position of the most coronal bone to implant contact in the initial image (00 M) was compared with x-rays from all subsequent control periods (12, 24, 36, and 60 M). The difference was defined as the marginal bone loss (MBL) index and was calculated separately for the proximal and distal surfaces of the implant. The value of this indicator was calculated first in pixels, and then converted to millimeters, assuming 19 pixels equals 1.15 mm. In the absence of a statistically significant difference between the MBL index on the proximal and distal surfaces of the implant, the mean value of the MBL index for each implant was calculated as the arithmetic mean of both surfaces. This value was then considered in the statistical calculations.

Statistical Analyses

Significance level was assumed as $P < 0.05$. The following statistical analyses were performed in this study: descriptive statistics, parametric and nonparametric tests, which compared the average values (the Mann-Whitney-Wilcoxon W test and the Student *t*-test), analysis of linear regression to assess dependency between parameters, and analysis of variance to determine impact of the clinical features on MBL. Statistical analyses were performed using Statgraphics Centurion XVI (StatPoint Technologies Inc., Warrenton, VA).

RESULTS

Patients and implants included in the study were divided into 2 groups depending on the type of implant-abutment connection. Table 1 shows the distribution of implants in both groups by sex and implantation site, whereas the sociodemographic and

clinical features of the study samples are characterized in Table 2.

This study proved that the type of implant-abutment connection was essential for optimal bone level. MBL values were significantly lower in group 2 (implants with internal cone connection) in all observation periods ($P < 0.05$). One year after loading, MBL was 0.68 ± 0.59 mm in group 2, whereas in group 1, MBL was higher at 0.99 ± 0.89 mm (Fig. 2). Two years after loading, MBL was 0.78 ± 0.80 mm in group 2, which was lower than that in group 1: 1.12 ± 1.00 mm (Fig. 3). Three years after loading, MBL reached 0.83 ± 0.87 mm in group 2, whereas in group 1, the MBL was higher at 1.22 ± 1.03 mm (Fig. 4). Sixty months after loading, the bone level was still positioned more coronally in group 2 compared with group 1 implants (0.96 ± 1.02 vs 1.30 ± 1.15 mm) (Fig. 5).

Both groups of implants achieved a 100% survival rate.

Table 2. Descriptive Statistics for the Two Study Groups

	Group 1—480 Internal Hex SPI Implants			Group 2—60 Internal Cone C1 Implants		
	Mean	Median	SD	Mean	Median	SD
Patient's age	43.8	45.5	14.13	46.17	48	13.73
Torque (Ncm)	45.46	45	10.04	44.66	45	9.47
Healing period (mo)	6.08	5	3.34	3.97	3	3.86
Implant diameter (mm)	3.78	3.75	0.17	3.72	3.75	0.14
Implant length (mm)	13.09	13.00	2.37	11.03	11.5	2.06
MBL_1Y (mm)	0.99	0.79	0.89	0.68	0.58	0.59
MBL_2Y (mm)	1.12	0.97	1.00	0.78	0.60	0.80
MBL_3Y (mm)	1.22	1.03	1.03	0.83	0.63	0.87
MBL_5Y (mm)	1.30	1.09	1.15	0.96	0.76	1.02

1Y indicates 1 year; 2Y, 2 years; 3Y, 3 years; 5Y, 5 years after loading. Group 1—480 internal hex SPI implants and group 2—60 internal cone C1 implants.

DISCUSSION

Comparing periimplant crestal bone level at the time of functional loading and in follow-up radiograms, its lower position can be observed most often. This lower position indicates the loss of bone at the neck of the implant. The difference in bone is called the MBL index. This indicator is commonly used to monitor the outcome of dental implant treatment and analyzed in the literature.^{10–12} In addition, this index is used to determine the success of dental implant treatment.^{13,14} Taking into account the criteria in the literature,

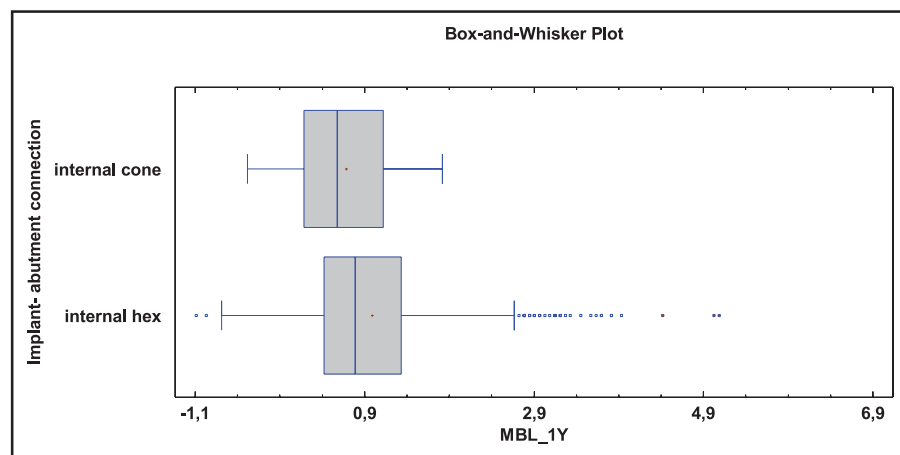


Fig. 2. Marginal bone loss around dental implants in relation to the implant-abutment connection 12 months after functional loading. The internal cone implant-abutment connection showed significantly less periimplant bone loss compared with the internal hex connection (0.68 ± 0.59 vs 0.99 ± 0.89 mm) ($P = 0.0102$) (one-way analysis of variance test).

it should be emphasized that, in this case, MIS C1 ensured successful treatment in 88.3% of implants, both after the first year and after 5 years of functional loading. AlphaBIO SPI implants were associated with lower treatment success—79.6% after the first year, and 80.4% after 5 years of loading. Both systems had a 100% implant survival rate.

There are 2 types of studies in the field of implant-abutment connection in the literature: *in vitro* studies and *in vivo* studies. *In vitro* studies concern the implant-abutment seal, which was evaluated by means of several bacterial species colonization,^{15–17} lipopolysaccharides,¹⁸ human saliva,¹⁹ or dyes,²⁰

and microgap observation using a scanning electron microscope.²¹ Most studies revealed greater tightness of the internal conical joint compared with other types of implant-abutment connections with statistical significance. However, even a conical joint could not completely eliminate the microleakage.^{22,23} Other *in vitro* studies took load performance into account and were grouped by Schmitt et al²⁴ in the following way: (a) fatigue performance and resistance,^{25,26} (b) bending moment/maximal load,²⁷ (c) preload loss (tightening/loosening torque) and cold welding,²⁸ and (d) stress and strain distribution in and around the implant-abutment interface.^{29,30}

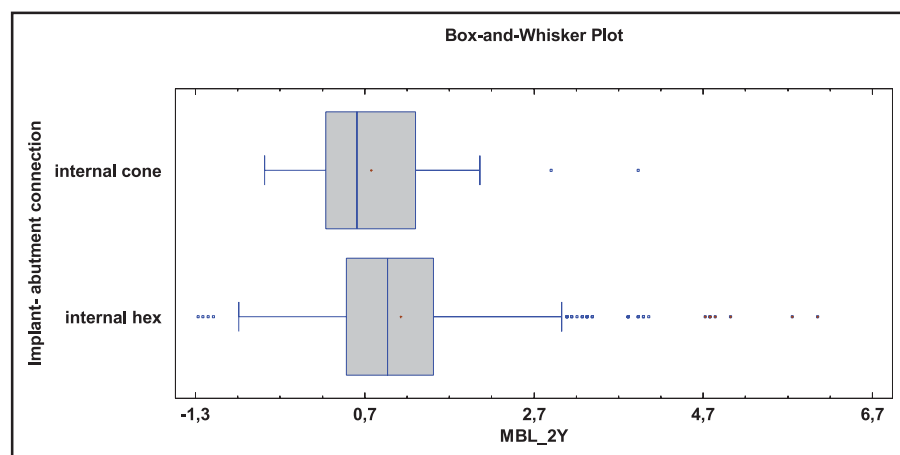


Fig. 3. Marginal bone loss around dental implants in relation to the implant-abutment connection 24 months after functional loading. The internal cone implant-abutment connection showed significantly less periimplant bone loss compared with the internal hex connection (0.78 ± 0.80 vs 1.12 ± 1.00 mm) ($P = 0.0101$) (one-way analysis of variance test).

These studies showed that the internal cone connection was the most resistant to abutment movements and retained a stable, nonenlarging microgap under occlusal forces.²⁴ In addition, internal cone connection proved to have the highest fracture resistance when compared with other connection types.^{31,32}

The second group of studies comprises clinical *in vivo* studies, performed either on animals or on humans. Radiographical evaluation of bone level around dental implants in dogs revealed more pronounced MBL in cases of external hex connection compared with internal cone.^{33,34}

However, the most accurate data can be obtained from human *in vivo* studies, which will be discussed in conjunction with the results of this study.

In this study, to evaluate whether the fact that implants were placed in different regions of the maxilla and mandible has any influence on MBL, a statistical comparison was conducted between implants placed in the anterior position and implants placed in the posterior position, as well as in the mandible and the maxilla. No difference was detected. Similarly, the effect of the length of the healing period and implant insertion torque was assessed, and there was no significant difference regarding those factors as well. Taking into account patient age, a similar distribution of this characteristic could be found in both groups in this study. In addition, the diameter of the most commonly used implant in both groups was 3.75 mm. The difference between both groups concerned the length of the most commonly used implant: in group 1, the 13-mm length implant was placed most often, whereas in group 2, the 11.5 mm implant was placed. According to many studies, the length of the implant does not affect MBL, and the above difference should be considered to have no effect on periimplant bone resorption.^{35–37} When analyzing the sex distribution in both groups, no difference was found. In group 1, the ratio of women to men was 54/46, whereas in group 2, the ratio was 59/41. However, taking into account the ratio of the number of implants placed in women to the number placed in men, there was

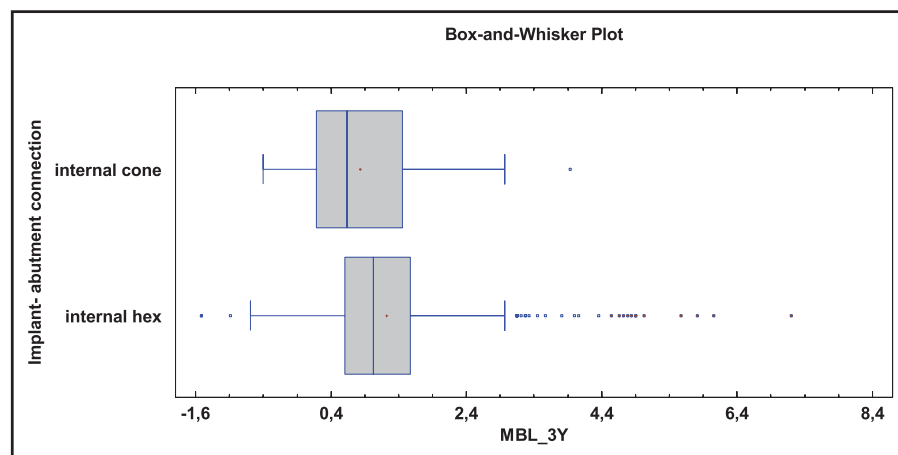


Fig. 4. Marginal bone loss around dental implants in relation to the implant-abutment connection 36 months after functional loading. The internal cone implant-abutment connection showed significantly less periimplant bone loss compared with the internal hex connection (0.83 ± 0.87 vs 1.22 ± 1.03 mm) ($P = 0.0070$) (one-way analysis of variance test).

a difference between the groups. In group 1, the ratio was 49/51, whereas in group 2, it was 70/30. In the light of the findings of Norton,³⁸ sex did not affect the bone around the implant. Other authors came to the same conclusion.^{39–41}

To avoid the possible impact of various titanium alloys and various surface modifications on periimplant bone, dental implants made of titanium alloy-grade 23 (Ti-6Al-4V-ELI) and with SLA surface were applied in both groups.^{6–8}

This study revealed that the type of implant-abutment connection is essential for bone preservation in the vicinity

of the dental implant. The internal cone connection was associated with lower bone loss (mean MBL after 5 years of loading was 0.96 mm) compared to internal hex connection (mean MBL after 5 years of loading was 1.3 mm) with statistical significance ($P < 0.05$) in every check-up period. Both types of connection provided a 100% survival rate.

In addition to this study, only 2 other reports were found in PubMed comparing the bone level around the implant in internal hex versus internal cone implant-abutment connection. The first study, performed by Pieri et al, is consistent with this study. That

study confirmed lower periimplant bone resorption in internal cone implant-abutment junctions in comparison with internal hex. The study included 40 patients who required extraction of a single premolar and underwent immediate implantation with immediate loading. The patients were divided into 2 groups: test group received implants with a conical connection and control group received implants with internal hex joint. After 12 months, the average MBL difference between the groups was 0.31 mm in favor of the conical joint with statistical significance.⁴²

The second clinical study was performed by Cannata et al. The authors divided 90 patients requiring implantation of a single implant in the mandible into 2 equal groups. In the first group, the authors placed implants with a conical connection, whereas in the second group, they placed the same type of implant but with an internal hex connection. The observation period lasted 12 months after loading, and no statistically significant difference between groups concerning MBL was found.⁴³ It should be noted that both of the above studies included a relatively small number of implants, and the observation time was short, which, in the opinion of the authors of this study, could have influenced the results obtained.

The explanation of a better conical joint outcome can be found in the numerous *in vitro* studies and finite-element analyses that were discussed in the first part of this section. Of particular importance is the limitation resulting from the micropump phenomenon, which is caused by the abutment's movement relative to the implant under occlusal forces. This movement results in aspiration of bacteria to the implant interior, where the bacteria undergo an inoculation process and are pumped out to the vicinity of the implant neck and cause bone resorption. The limitation of this phenomenon is associated with the tightness and mechanical stability of the conical versus internal hex connection,^{2,44–46} as well as strict adherence to the torque values recommended by the manufacturers when screwing the abutment to the implant.⁹

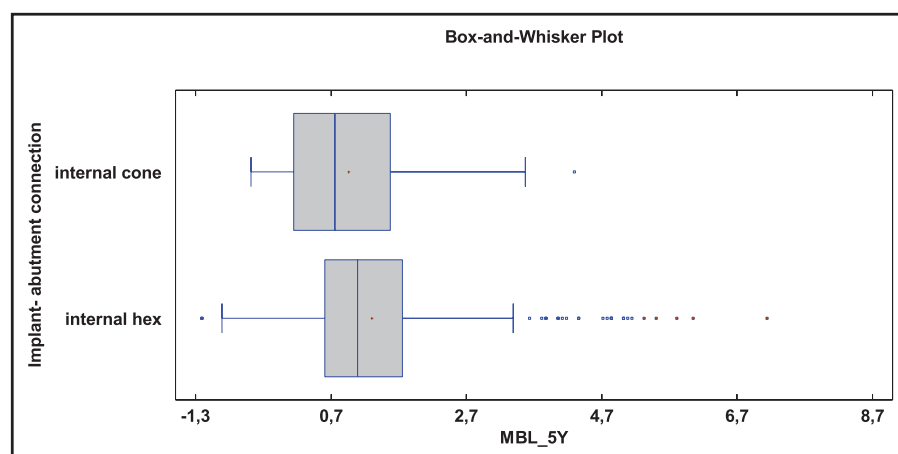


Fig. 5. Marginal bone loss around dental implants in relation to the implant-abutment connection 60 months after functional loading. The internal cone implant-abutment connection showed significantly less periimplant bone loss compared with the internal hex connection (0.96 ± 1.02 vs 1.30 ± 1.15 mm) ($P = 0.0292$) (one-way analysis of variance test).

CONCLUSION

The internal cone implant-abutment connection causes less peri-implant bone resorption compared with the internal hexagon connection. MBL is lower in cases of internal cone joint in long-term follow-up. Both types of connections ensure a 100% implant survival rate after 5 years of observation.

DISCLOSURE

The authors claim to have no financial interest, either directly or indirectly, in the products or information listed in the article.

APPROVAL

The study was approved by the research ethics committee of the University of Lodz (RNN/133/13/KB 19.02.2013).

REFERENCES

1. Khraisat A, Stegaroiu R, Nomura S, et al. Fatigue resistance of two implant/abutment joint designs. *J Prosthet Dent*. 2002;88:604–610.
2. Verdugo CL, Núñez GJ, Avila AA, et al. Microleakage of the prosthetic abutment/implant interface with internal and external connection: In vitro study. *Clin Oral Implants Res*. 2014;25:1078–1083.
3. Canullo L, Penarrocha-Oltra D, Soldini C, et al. Microbiological assessment of the implant-abutment interface in different connections: Cross-sectional study after 5 years of functional loading. *Clin Oral Implants Res*. 2015;26:426–434.
4. Kitagawa T, Tanimoto Y, Odaki M, et al. Influence of implant/abutment joint designs on abutment screw loosening in a dental implant system. *J Biomed Mater Res B Appl Biomater*. 2005;75:457–463.
5. Merz BR, Hunenbart S, Belser UC. Mechanics of the implant–abutment connection: An 8-degree taper compared to a butt joint connection. *Int J Oral Maxillofac Implants*. 2000;15:519–526.
6. Alphabio.pl. *Alpha Bio Polska* [online]; 2019. Available at: https://alphabio.pl/lekarz/baza_wiedzy/powierzchnia_nanotec. Accessed March 23, 2019.
7. Alpha-bio.net. *NanoTec Implant Surface* [online]; 2019. Available at: <https://alpha-bio.net/global/products/implant-system/nanotec-implant-surface/>. Accessed March 23, 2019.
8. *Mis-implants.com* [online]; 2019. Available at: https://www.mis-implants.com/upload/PDF/Products/Implants/MIS_C1_Catalog.pdf. Accessed Mar 23, 2019.
9. Baggi L, Di Girolamo M, Mirisola C, et al. Microbiological evaluation of bacterial and mycotic seal in implant systems with different implant-abutment interfaces and closing torque values. *Implant Dent*. 2013;22:344–350.
10. Galindo-Moreno P, León-Cano A, Ortega-Oller I, et al. Marginal bone loss as success criterion in implant dentistry: Beyond 2 mm. *Clin Oral Implants Res*. 2015;26:e28–e34.
11. Hingsammer L, Watzek G, Pommer B. The influence of crown-to-implant ratio on marginal bone levels around splinted short dental implants: A radiological and clinical short term analysis. *Clin Implant Dent Relat Res*. 2017;19:1090–1098.
12. Kim YT, Lim GH, Lee JH, et al. Marginal bone level changes in association with different vertical implant positions: A 3-year retrospective study. *J Periodontal Implant Sci*. 2017;47:231–239.
13. Albrektsson T, Zarb G, Worthington P, et al. The long-term efficacy of currently used dental implants: A review and proposed criteria of success. *Int J Oral Maxillofac Implants*. 1986;1:11–25.
14. Wennström J, Palmer R. Consensus report of session 3: Clinical trials. In: Lang NP, Karring T, Lindhe J, eds. *Proceedings of the 3rd European Workshop on Periodontology: Implant Dentistry*. Berlin, Germany: Quintessence; 1999:255–259.
15. Tesmer M, Wallet S, Koutouzis T, et al. Bacterial colonization of the dental implant fixture–abutment interface: An in vitro study. *J Periodontol*. 2009;80:1991–1997.
16. Koutouzis T, Wallet S, Calderon N, et al. Bacterial colonization of the implant–abutment interface using an in vitro dynamic loading model. *J Periodontol*. 2011;82:613–618.
17. Teixeira W, Ribeiro RF, Sato S, et al. Microleakage into and from two-stage implants: An in vitro comparative study. *Int J Oral Maxillofac Implants*. 2011;26:56–62.
18. Harder S, Dimaczek B, Acil Y, et al. Molecular leakage at implant–abutment connection—in vitro investigation of tightness of internal conical implant–abutment connections against endotoxin penetration. *Clin Oral Investig*. 2010;14:427–432.
19. do Nascimento C, Miani PK, Pedrazzi V, et al. Leakage of saliva through the implant–abutment interface: In vitro evaluation of three different implant connections under unloaded and loaded conditions. *Int J Oral Maxillofac Implants*. 2012;27:551–560.
20. Gross M, Abramovich I, Weiss EI. Microleakage at the abutment-implant interface of osseointegrated implants: A comparative study. *Int J Oral Maxillofac Implants*. 1999;14:94–100.
21. Jansen VK, Conrads G, Richter EJ. Microbial leakage and marginal fit of the implant–abutment interface. *Int J Oral Maxillofac Implants*. 1997;12:527–540.
22. Aloise JP, Curcio R, Laporta MZ, et al. Microbial leakage through the implant–abutment interface of Morse taper implants in vitro. *Clin Oral Implants Res*. 2010;21:328–335.
23. Ranieri R, Ferreira A, Souza E, et al. The bacterial sealing capacity of Morse Taper implant–abutment systems in vitro. *J Periodontol*. 2015;86:696–702.
24. Schmitt CM, Nogueira-Filho G, Tenenbaum HC, et al. Performance of conical abutment (Morse Taper) connection implants: A systematic review. *J Biomed Mater Res A*. 2014;102:552–574.
25. Seetoh YL, Tan KB, Chua EK, et al. Load fatigue performance of conical implant–abutment connections. *Int J Oral Maxillofac Implants*. 2011;26:797–806.
26. Ribeiro CG, Maia ML, Scherrer SS, et al. Resistance of three implant–abutment interfaces to fatigue testing. *J Appl Oral Sci*. 2011;19:413–420.
27. Coppede AR, Bersani E, de Mattos Mda G, et al. Fracture resistance of the implant–abutment connection in implants with internal hex and internal conical connections under oblique compressive loading: An in vitro study. *Int J Prosthodont*. 2009;22:283–286.
28. Piermatti J, Yousef H, Luke A, et al. An in vitro analysis of implant screw torque loss with external hex and internal connection implant systems. *Implant Dent*. 2006;15:427–435.
29. Saidin S, Abdul Kadir MR, Sulaiman E, et al. Effects of different implant–connections on micromotion and stress distribution: Prediction of microgap formation. *J Dent*. 2012;40:467–474.
30. Pellizzer EP, Carli RI, Falcón-Antenucci RM, et al. Photoelastic analysis of stress distribution with different implant systems. *J Oral Implantol*. 2014;40:117–122.
31. Norton MR. An in vitro evaluation of the strength of a 1-piece and 2-piece conical abutment joint in implant design. *Clin Oral Implants Res*. 2000;11:458–464.
32. Norton MR. Assessment of cold welding properties of the internal conical

interface of two commercially available implant systems. *J Prosthet Dent*. 1999; 81:159–166.

33. Weng D, Nagata MJ, Leite CM, et al. Influence of microgap location and configuration on radiographic bone loss in nonsubmerged implants: An experimental study in dogs. *Int J Prosthodont*. 2011;24:445–452.

34. Weng D, Nagata MJ, Bosco AF, et al. Influence of microgap location and configuration on radiographic bone loss around submerged implants: An experimental study in dogs. *Int J Oral Maxillofac Implants*. 2011;26:941–946.

35. Mumcu E, Bilhan H, Cekici A. Marginal bone loss around implants supporting fixed restorations. *J Oral Implantol*. 2011;37:549–558.

36. Rasouli Ghahroudi A, Talaeepour A, Mesgarzadeh A, et al. Radiographic vertical bone loss evaluation around dental implants following one year of functional loading. *J Dent (Tehran)*. 2010; 7:89–97.

37. Sotto-Maior BS, Mercuri EG, Senna PM, et al. Evaluation of bone remodeling around single dental implants

of different lengths: A mechano-biological numerical simulation and validation using clinical data. *Comput Methods Biomech Biomed Engin*. 2016;19:699–706.

38. Norton MR. The influence of insertion torque on the survival of immediately placed and restored single-tooth implants. *Int J Oral Maxillofac Implants*. 2011;26:1333–1343.

39. Wagenberg B, Froum SJ. Long-term bone stability around 312 rough-surfaced immediately placed implants with 2–12-year follow-up. *Clin Implant Dent Relat Res*. 2015;17:658–666.

40. Pikner SS, Gröndahl K, Jemt T, et al. Marginal bone loss at implants: A retrospective, long-term follow-up of turned Brånemark System implants. *Clin Implant Dent Relat Res*. 2009;11:11–23.

41. Pikner SS, Gröndahl K. Radiographic analyses of “advanced” marginal bone loss around Branemark dental implants. *Clin Implant Dent Relat Res*. 2009;11:120–133.

42. Pieri F, Aldini NN, Marchetti C, et al. Influence of implant–abutment interface design on bone and soft tissue levels around immediately placed

and restored single-tooth implants: A randomized controlled clinical trial. *Int J Oral Maxillofac Implants*. 2011;26:169–178.

43. Cannata M, Grandi T, Samarani R, et al. A comparison of two implants with conical vs internal hex connections: 1-year post-loading results from a multicentre, randomized controlled trial. *Eur J Oral Implantol*. 2017;10:161–168.

44. Hermann JS, Schoolfield JD, Schenk RK, et al. Influence of the size of the microgap on crestal bone changes around titanium implants: A histometric evaluation of unloaded non-submerged implants in the canine mandible. *J Periodontol*. 2001;72:1372–1383.

45. Dias Resende CC, Carolina Castro G, Pereira LM, et al. Influence of the prosthetic index into Morse Taper implants on bacterial microleakage. *Implant Dent*. 2015;24:547–551.

46. Macedo JP, Pereira J, Vahey BR, et al. Morse taper dental implants and platform switching: The new paradigm in oral implantology. *Eur J Dent*. 2016;10: 148–154.